

CASE STUDY

- 95% WOUND REDUCTION
- TOTAL HEALING IN 8 WEEKS
- 1 ACTIGRAFT APPLICATIONS

PATIENT:

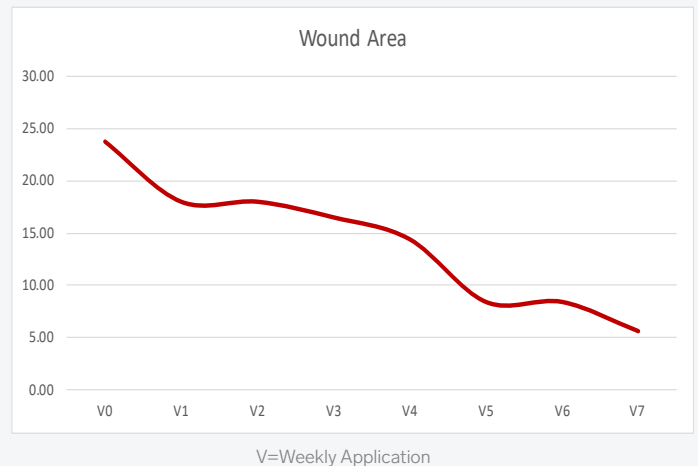
67 year-old, female.

WOUND HISTORY:

- ESRD
- DM2
- PVD
- Gangrene of the great toe
- Failed ray amputation an TMA
- Refused BKA

PAST TREATMENTS:

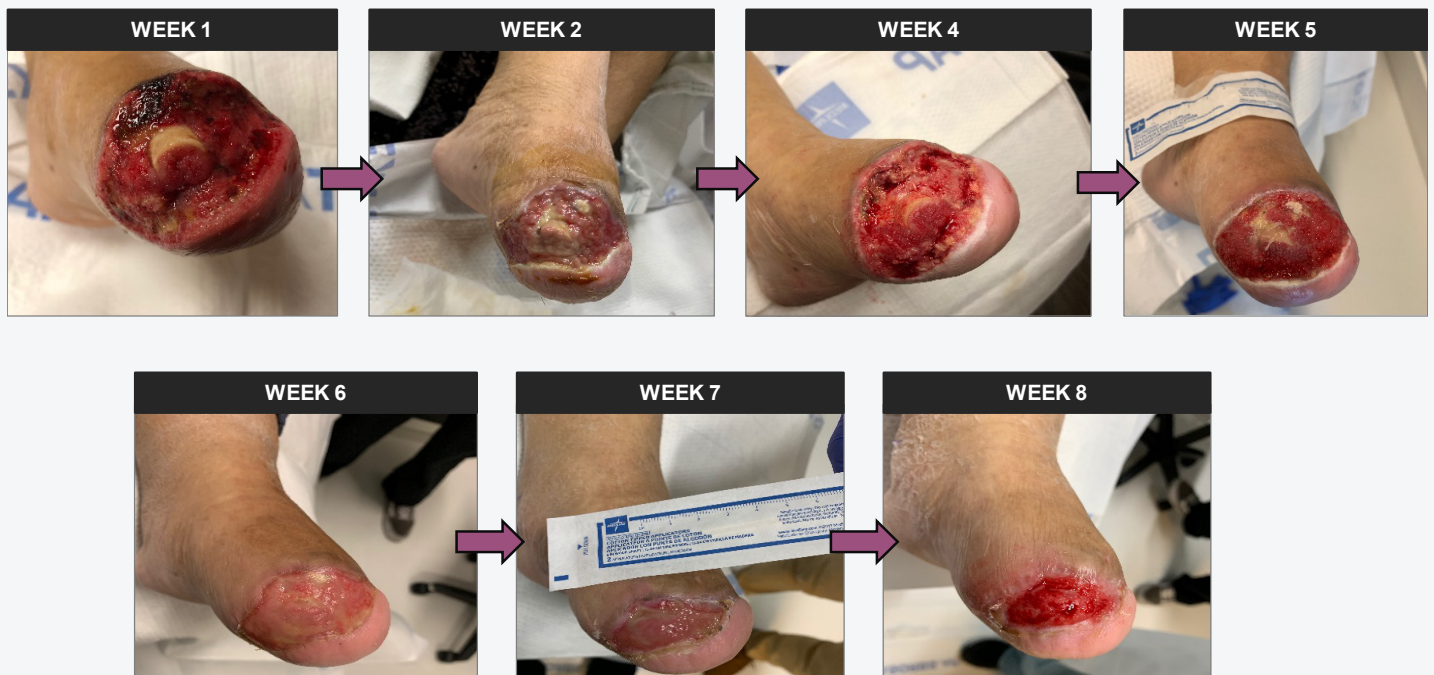Wound Vac & HBO



OFFLOADING:

N/A

ACTIGRAFT TREATMENT PROGRESSION:



CASE STUDY

- 100% WOUND REDUCTION
- TOTAL HEALING IN 5 WEEKS
- 4 ACTIGRAFT APPLICATIONS

PATIENT:

37 year-old, female.

PAST MEDICAL HISTORY:

Diabetic

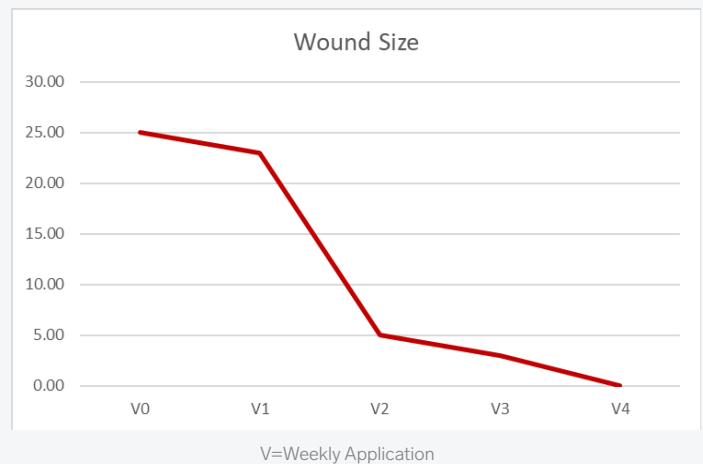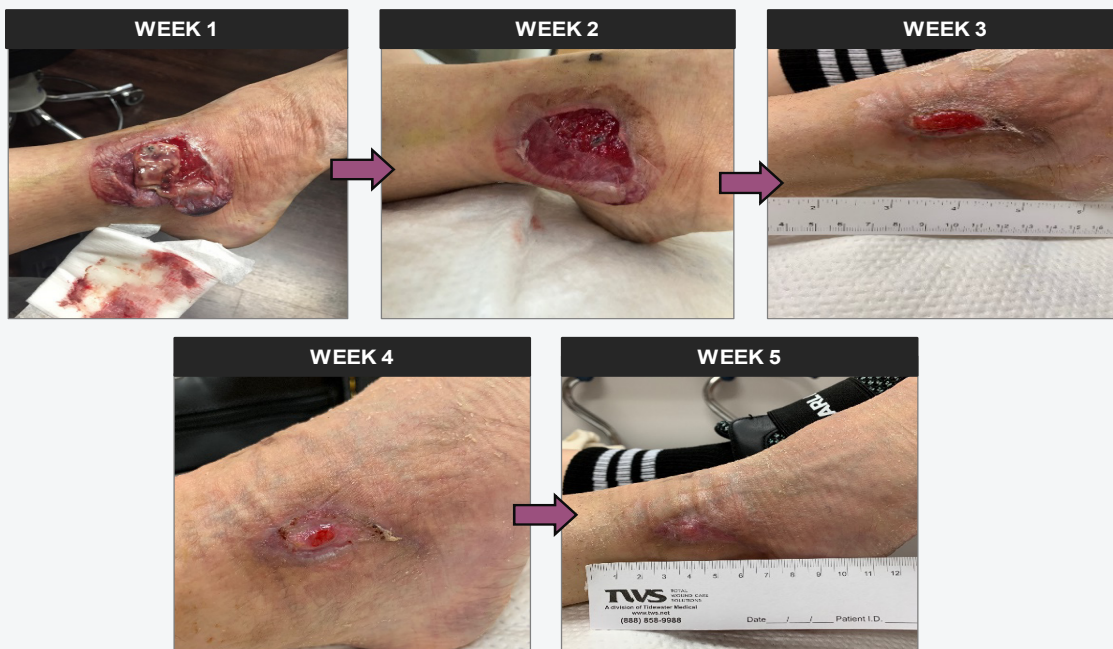WOUND HISTORY:

- Right lateral malleolus
- Latrogenic vascular ulcer
- Duration: 2 months
- Day 1 = 16 cm²

PAST TREATMENTS:

Debridement, Silver Alginate, Oral and IV Antibiotics, Collagen.

ACTIGRAFT TREATMENT PROGRESSION:



OFFLOADING:

N/A