

## Efficacy and Safety of a Novel Autologous Wound Matrix in the Management of Complicated, Chronic Wounds: A Pilot Study

Igal Kushnir, MD<sup>1</sup>; Alon Kushnir<sup>1</sup>; Thomas E. Serena, MD<sup>2</sup>; and Doron Garfinkel, MD<sup>3</sup>

*Wounds* 2016;28(9):317-327

From <sup>1</sup>RedDress Ltd, Pardes Hanna, Israel; <sup>2</sup>Clinical Research, Serena Group Wound and Hyperbaric Centers, Warren, PA; and <sup>3</sup>Homecare Service, Israel Cancer Association and Geriatric-Palliative Service, Wolfson Medical Center, Holon, Israel

Address correspondence to:

**Igal Kushnir, MD**

RedDress Ltd.

Shkedim St. 1

Pardes Hanna, Israel

dr@igalkushnir.com

*Disclosure:* Dr. Kushnir and Alon Kushnir are shareholders in RedDress Ltd, Pardes Hanna, Israel, which sponsored this study. RedDress Ltd also sponsors a clinical trial for this product, now in Phase II (ClinicalTrials.gov identifier: NCT01396837).

**Abstract:** *Introduction.* The objective of this pilot study was to evaluate the efficacy and safety of a novel method using an autologous whole blood clot formed with the RedDress Wound Care System (RD1, RedDress Ltd, Israel), a provisional whole blood clot matrix used in the treatment of chronic wounds of various etiologies. *Methods and Materials.* Patients were treated at the bedside with the whole blood clot matrix. Blood was withdrawn from each patient using citrate, mixed with a calcium gluconate/kaolin suspension, and injected into an RD1 clotting tray. Within 10 minutes, a clot was formed, placed upon the wound, and fixed with primary and secondary dressings. Wounds were redressed weekly with a whole blood clot matrix. Treatment was terminated when complete healing was achieved, or when the clinician determined that the wound could not further improve without additional invasive procedures. *Results.* Seven patients with multiple and serious comorbidities and 9 chronic wounds were treated with 35 clot matrices. Complete healing was achieved in 7 of 9 wounds (78%). In 1 venous ulcer with a nonhealing fistula, 77% healing was achieved. Treatment was terminated in 1 pressure ulcer at 82% closure, because an unexpected mechanical trauma resulted in deterioration; this was the only adverse event reported, unrelated to the product. No systemic adverse events occurred. *Conclusions.* This pilot study demonstrates the in vitro autologous whole blood clot matrix is effective and safe for treating patients with chronic wounds of different etiologies. A larger clinical trial is needed to assess the relative success rate of the matrix in different types of wounds in a diverse population with comorbidities.

**Key words:** chronic wounds, autologous wound matrix, safety, efficacy, blood clot

**H**uman skin, when injured, is capable of carrying out self-repair to restore tissue integrity.<sup>1</sup> Wound healing involves 4 overlapping processes, beginning immediately at the onset of injury with hemostasis and transitioning to inflammation, proliferation, and remodeling.<sup>2,3</sup> In an open wound, platelets initiate the healing process with the activation of the coagulation cascade, resulting in the formation of a fibrin blood clot that plugs severed blood vessels and fills in tissue discontinuity at the wound site.<sup>2,8</sup> The blood clot, having reestablished hemostasis, is also essential to in-

flammation, with its fibrin scaffold that serves as a protective, provisional extracellular matrix (ECM) that harbors the cytokines and growth factors (eg, interleukin, transforming growth factor- $\beta$ , platelet-derived growth factor, and vascular endothelial growth factor) released by the degranulation of activated platelets.<sup>5,9,10</sup> The clot also recruits endothelial cells and fibroblasts, which begin to synthesize a permanent ECM at the wound bed, in addition to inducing the migration of neutrophils, and wound macrophages. As the clot dries out and becomes a protective scab, under which tissue remodeling takes place undisturbed, the fibrin is replaced by fibronectin and hyaluronan, and the scab falls off to reveal a collagenous scar.<sup>10,11</sup>

The normal wound healing process is, however, a delicate trajectory. Every acute wound has the risk of becoming a chronic wound if the healing process is stalled for up to 3 months or more.<sup>12</sup> Multiple patient and wound factors can delay the complex healing process.<sup>12-14</sup> The patient's age, weight, health and nutritional status, and lifestyle habits, such as smoking, can negatively impact wound healing. Wound type, size, depth, the presence of infection, and the lack of an adequate blood supply in the wound can also delay healing.<sup>12-15</sup>

Moist wound therapy has been the standard of wound care since preclinical research performed by George D. Winter in 1962.<sup>16</sup> Wound dressings protect the wound from infection by providing a moist, warm environment that also facilitates reepithelialization and the migration of the cells at the wound margin across the wound bed. The variety of wound dressings available today vary from standard gauze to more advanced options that use biologic and hemostatic agents. A new therapeutic option for wounds is the use of biologic scaffold materials, such as collagen, applied to wounds as a whole provisional ECM, as part of the ECM, or as part of a hybrid scaffold made of synthetic and biologic materials.<sup>15,17,18</sup> While traditional dressings aim to protect and hydrate the wound, biologic scaffolds serve as a wound microenvironment to promote the healing processes and tissue formation.

An autologous, biodegradable scaffold has recently been developed that recreates the functional wound healing environment of the fibrin scaffold with a minimal risk of immunorejection. The RedDress Wound Care System (RD1, RedDress Ltd, Israel), a provisional whole blood clot matrix, is created *in vitro* at the bedside from blood drawn from the patient, with the aid of citrate, the common anticoagulant. The blood is then mixed with a suspension of calcium gluconate to reinitiate the clotting

cascade, and kaolin, a layered insoluble aluminum silicate that is used in hemostatic dressings to enable control of the coagulation time and final clot homogeneity.<sup>19-25</sup> The clot is then formed and anchored directly over the wound with a Steri-Strip skin closure (3M, St. Paul, MN) and secured with standard dressings to serve as a healing initiator and moderator and as a functional, natural ECM.

The objective of this small pilot study was to evaluate the efficacy of the continuous weekly application of the whole blood clot matrix on the healing of chronic wounds and the safety of the matrix, as defined by the occurrence of adverse events.

## Methods and Materials

This study was a prospective, interventional pilot study of patients treated for their wounds with whole blood clot matrix kits at Shoham Geriatric Medical Center (SGMC) in Pardes Hanna, Israel. The main outcome measure was complete healing, defined as complete wound closure. The study protocol was approved by the Ethics Committee of SGMC, and the study complied with the Declaration of Helsinki. The study was sponsored by RedDress Ltd, Israel, which provided the clotting kits and standard minor surgery kits, trained the study nurses and physicians on proper use of the kits, assisted with the development of the trial protocol, and monitored the data collection process.

*Patient eligibility and enrollment.* Study participants were wound care patients hospitalized in the geriatric-palliative department and in several skilled nursing departments at SGMC from June 2009 to January 2010. The eligible wound types considered for this study included acute wounds or hard-to-heal wounds. Hard-to-heal wounds included wounds with healing delayed for more than 1 month, Stage III or IV pressure ulcers, and Category 3 skin tears. Pressure ulcers were staged according to previous (2007-2014) National Pressure Ulcer Advisory Panel and European Pressure Ulcer Advisory Panel staging<sup>26</sup> and tear wounds were categorized according to the Payne-Martin Classification for Skin Tears.<sup>27,28</sup>

Each patient or their guardian gave written informed consent for study participation prior to the patient's inclusion in the study. All patients had already been treated locally for several types of wounds with the standard procedures and dressings. Patient inclusion criteria were patients 21-99 years of age with a life expectancy of > 6 months and with 1 venous ulcer, pressure ulcer, tear wound, or amputation site who agreed to sign the consent form. Exclusion criteria included patients with

**Table 1.** Quantities of whole blood clot matrix materials to be used per tray size

Tray size (cm <sup>2</sup> )	Syringe size (mL)	CPDA-1 (mL)	Blood to be extracted (mL)	Calcium gluconate + kaolin suspension (coagulation activator) (mL)
14.5	20	1.5	10	2
26.4	20	2	13	2.5
64	50	4	30	5

CPDA-1: citrate phosphate dextrose adenine

wounds with an area > 100 cm<sup>2</sup>, cancerous wounds, a life expectancy < 6 months, sepsis proven by blood test 2 weeks prior to enrollment, known coagulation disease or intravenous heparin administration, anemia (< 8 g/dL), and for whom the withdrawal of 30 mL of blood was either not clinically recommended or could not technically be performed. Once a patient was enrolled in the study, all previous topical wound care treatments and dressings were stopped 5 days prior to initiating the application of the matrix.

*Whole blood clot matrix preparation.* The study was conducted using sterile, single-use whole blood clot kits. Each kit contained a blood withdrawal kit with sterile syringes; a citrate phosphate dextrose adenine (CPDA-1) blood collection bag; a sterile needle and tubing set; a coagulation initiator and accelerator component comprised of a 10 mL sterile ampoule of 10% calcium gluconate injection (APP Pharmaceuticals, Schaumburg, IL); a 10 mL sterile syringe; 30 mg of pharmaceutical grade kaolin powder (Charles B. Chrystal Co Inc, Larchmont, NY) sterilized in a vial; and 3 sizes of sterile, single-use clotting trays (small, 14.5 cm<sup>2</sup>; medium, 26.4 cm<sup>2</sup>; and large, 64 cm<sup>2</sup>) with medical cotton gauze stretched across the bottom of each clotting tray. The gauze is embedded into the clot during the coagulation process, contributing to its robustness, and enabling the care provider to safely transfer it to the wound, to trim it, and to anchor it to the wound as required. For each tray size, there are specific instructions for the amount of CPDA-1 to be used, blood to be extracted, and coagulation activator (the calcium gluconate + kaolin mixture) to be used (Table 1). The whole blood clot kit is disposable and was discharged after single use according to hospital regulations.

Minor surgery kits were additionally provided during this study to ensure the care provider had all the possible tools that might have been required during the wound care process. These kits included a sterile surface, sterile gloves, sterile gauze, sterile plate, sterile scissors, sterile forceps, and a single-use chlorhexidine swab.

Two nurses and 1 physician employed by SGMC were trained by the manufacturer on the proper use of the whole blood clot kits and were directly involved in the preparation of the product in the study. The nurses performed all the matrix kit preparation and placement work under the supervision of the physician.

To prepare the whole blood clot matrix, the nurse first selected the appropriate tray according to the wound size. For this purpose, the wound size was determined by measuring the maximum length between 2 points on the wound edges. A clotting tray larger than the wound was selected to ensure the whole blood clot matrix would cover the whole wound area in addition to at least 0.5 cm of intact skin surrounding the wound. The tray was laid on a flat, horizontal surface.

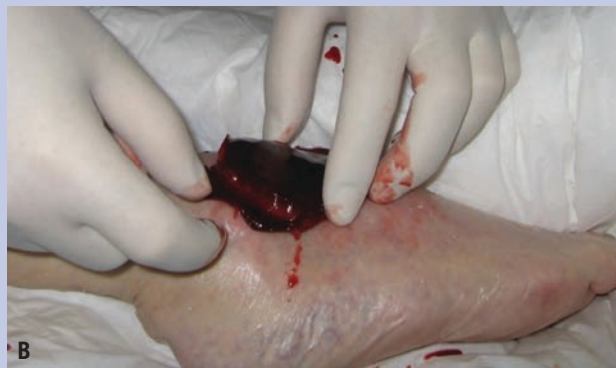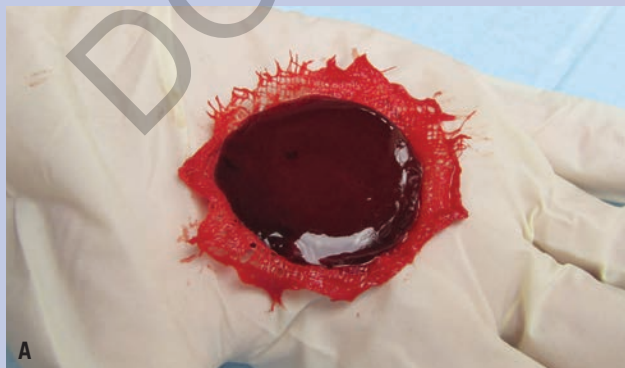
Next, the wound bed was prepared for the clot matrix application according to the standard practice of debridement, usually with sterile saline, as necessary. The current and past clinical status of the patient and their wound was documented. The type of wound, location, and wound history (eg, previous treatments, adverse events, frequency of dressing changes, and wound size changes) were recorded. Wound assessment included the percent of granulation, epithelialization, necrosis, and slough; the type and amount of exudate; visual signs of infection based on color, heat, odor, swelling, and pain; and wound depth and dimensions. The wound was photographed with a digital camera at a fixed distance of 50 cm from the wound, facing the wound center, with a disposable ruler labeled with the date, patient number and wound number) placed in close proximity to the wound edges.

*Whole blood clot matrix procedure and application.* For preparation of the clot, the nurse filled a syringe (20 mL or 50 mL, according to the selected tray) with the appropriate amount of CPDA-1 and extracted venous blood from the patient. Blood withdrawal and handling was performed according to the hospital's precautionary guidelines. There was no threshold for the number of failed attempts at vein puncture before deciding to abort the

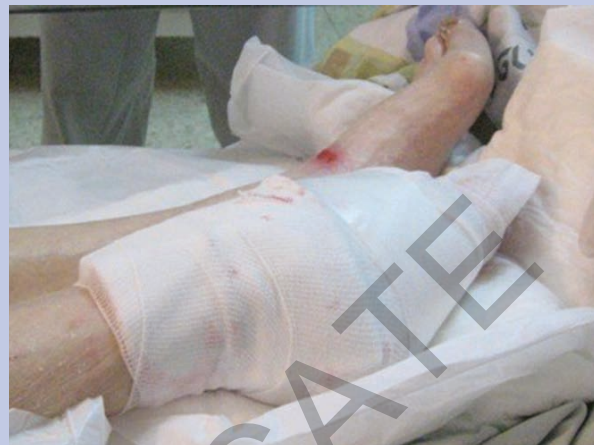application session; the provider had the clinical judgment to decide to stop venipuncture if necessary. Five mL of calcium gluconate was mixed in a sterile vial with 35 mg of sterile kaolin white powder. A specified amount (Table 1) of the mixture was extracted using the syringe which already contained the citrated blood. The suspension was gently mixed for 10 seconds. The coagulating blood was injected into the preselected clotting tray (Figure 1). The nurse then waited for 10 minutes for the clot



**Figure 1.** The selected clotting tray was placed on a flat, horizontal surface. After being mixed with the kaolin + calcium gluconate suspension, the coagulated blood was injected into the clotting tray.



**Figure 2.** (A) After 10 minutes in the clotting tray, the whole blood clot matrix was formed from the coagulated blood; and (B) the nurse, using sterile gloves, removed the matrix from the tray and placed it over the wound.



**Figure 3.** After the clot matrix was affixed to the wound, primary and secondary dressings were applied.

to be created. Next, the nurse opened the clotting tray using sterile gloves and gently lifted the whole blood clot matrix (Figure 2A). The clot was placed on the wound, with the embedded gauze pad facing upwards (Figure 2B) and anchored to the wound via the gauze edges. Primary and secondary dressings further affixed the clot to the wound (Figure 3).

*Follow-up and reapplication.* The follow-up schedule involved monitoring and reapplication visits, as required. Monitoring visits were conducted every 2 days. During these sessions, only primary and secondary dressings were removed and changed, while the whole blood clot matrix stayed on the wound. The visit included visual inspection of the exposed outer surface of the product to document the adherence of the clot to the wound and inspection of the wound periphery for adverse events such as infection.

**Table 2.** Patient and wound characteristics.

Patient No.	Sex	Age (years)	Comorbidities	Ambulatory Status	Wound No.	Etiology	Location	Size (cm <sup>2</sup> )	Wound Duration	Cat/ Stage
1	Female	88	Stroke with paralysis on right side Hypertension Malnutrition Severe dementia Hypoalbuminemia Chronic anemia	Bedridden	2	Venous ulcer with fistula	Right, dorsal foot	3.1	12 weeks	N/A
					3	Venous ulcer	Left, dorsal foot	1.4	12 weeks	N/A
4	Female	48	Multiple sclerosis Severe dementia Obesity	Limited self-mobility	4	Pressure ulcer	Right heel	3.6	12 weeks	III
6	Male	90	Diabetes Severe dementia Chronic anemia Hypoalbuminemia Blindness Alcoholism	Bedridden	6	Pressure ulcer	Left heel	4.7	4 weeks	III
					8	Pressure ulcer	Right heel	3.2	4 weeks	III
7	Female	73	Diabetes Hypertension Schizophrenia and psychiatric symptoms Right hip fracture Severe dementia Chronic anemia Hypoalbuminemia Lipidemia Blindness	Bedridden	7	Venous ulcer	Right shin	2.8	12 weeks	N/A
8	Female	90	Huntington's disease Severe dementia Chronic anemia Lipidemia	Bedridden	9	Pressure ulcer	Sacrum	6.6	12 weeks	III
9	Female	93	Severe dementia with general deterioration Tibia fracture	Bedridden	1	Tear wound	Left shin	28.1	3 weeks	Cat 3
10	Male	32	None	Full ambulation	5	Traumatic amputation	Middle finger tip of right hand	0.89	4.3 weeks	N/A

N/A indicates the wound was unstageable; Cat: category

Reapplication visits occurred every 6 to 9 days, during which the clot matrix was removed, and a new clot was created and applied, as necessary. After removing the whole blood clot matrix, the wound was assessed and a digital photograph taken, as previously described. If the wound remained open, the wound bed was gently cleansed and prepped for clot reapplication, according to

standard procedures using gauze and saline. The whole blood clot procedure and application was performed as previously described.

There was no fixed treatment study period. Each wound was continuously dressed with a clot matrix until complete healing was achieved, or until there was a clinical determination that the wound could not further

improve without additional invasive procedures, such as surgery to remove a fistula at a different facility, as SGMC does not have a surgical department.

**Wound photographic assessment.** The nurse took digital wound photographs, which were then analyzed by the principal investigator using ImageJ image processing and analysis software (National Institute of Health, Bethesda, MD). Assessment involved measurement of the number of pixels in 10 mm counted on the ruler in each photograph; delineations of the wound edges and documentation of automatic pixels area output of the software (repeated 3 times); calculations of the average pixels area of the 3 separate delineations; conversion of the pixels area units to mm<sup>2</sup> by the measured pixels per 10 mm; and documentation of the final result in the patient's case

report form for the specific date the picture was taken. Data collection was monitored by a clinical research associate of the sponsor, which performed the data collection analysis.

**Safety assessment.** The whole blood clot matrix was assessed for safety based on the occurrence of adverse events, which were defined and graded according to the Medical Dictionary for Regulatory Activities standardized terms.<sup>29</sup> Safety assessments occurred during follow-up visits every 2 days during week 1, every 4 days during weeks 2 and 3, and then weekly beginning in week 4. Safety assessments occurred up to 10 weeks or until complete wound closure. Adverse events, serious adverse events, and discontinuations due to adverse events were recorded on the patient's case report form and reported to the ethics committee and the sponsor within 24 hours of recognition by the principal investigator.

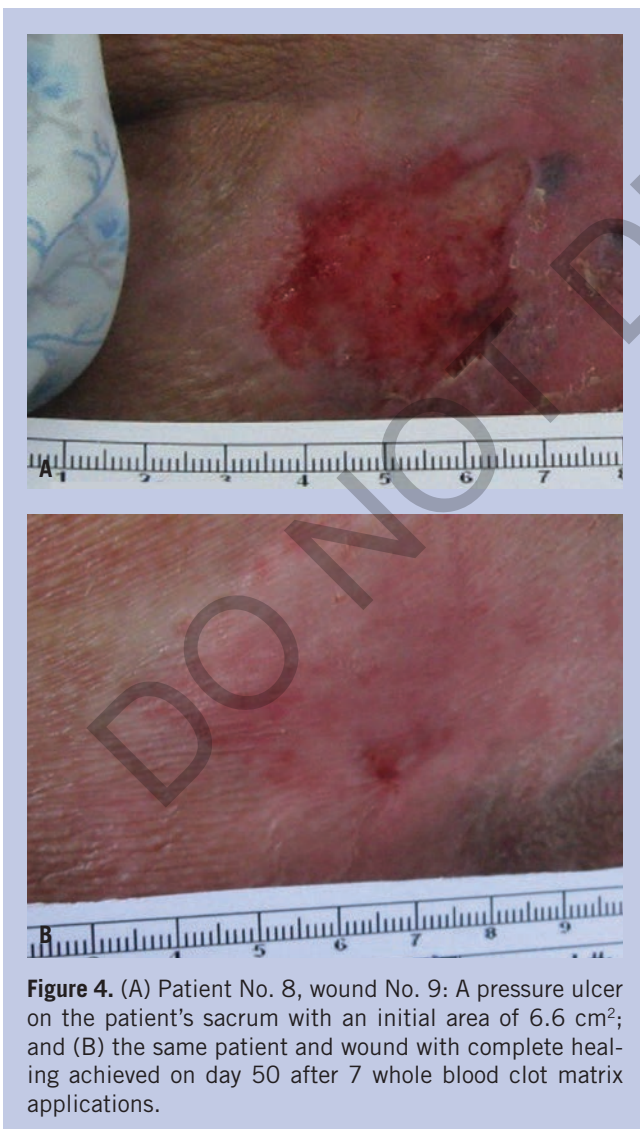The criteria to cease application of the whole blood clot matrix were based on the following wound deterioration factors: infection of the wound as noted by care provider based on visual analysis (eg, redness, heat, and/or exudate), increased wound size by more than 30%, and inability to withdraw blood from the patient.

## Results

**Demographics.** From June 2009 to January 2010, 10 patients were screened for study eligibility. One patient was ineligible to participate in the study because the wound was completely covered in necrotic tissue. Two patients were ineligible due to having a life expectancy of less than 1 year. Seven patients (2 males and 5 females) participated in this study, with a wide range of ages (32–90 years), multiple and serious comorbidities, and wounds of different etiologies, duration, and severity (Table 2). Most of the patients were bedridden (5, 71.4%), and only 1 patient was fully ambulatory. There were 9 study wounds; patients No. 1 and 6 each had 2 wounds. All other patients had 1 wound.

**Status of whole blood clot matrix preparation and application and safety.** All wounds were treated with the whole blood clot matrix. In total, 35 clots were created and applied to the wounds.

The average quantity of blood withdrawn per treatment session was 13.1 mL. Blood was withdrawn from all patients without interruption, and there were no excessive venipuncture attempts that could have resulted in large amounts of blood withdrawal. During the 35 whole blood clot matrix application sessions, only 1 vein puncture was needed for each of the blood withdrawal



**Figure 4.** (A) Patient No. 8, wound No. 9: A pressure ulcer on the patient's sacrum with an initial area of 6.6 cm<sup>2</sup>; and (B) the same patient and wound with complete healing achieved on day 50 after 7 whole blood clot matrix applications.

**Table 3.** Results of whole blood clot matrix application(s) and wound healing outcomes

Patient No.	Wound No.	Etiology	Location	Number of days dressed with clot matrix	Number of clot matrix applications	Initial wound area (cm <sup>2</sup> )	Final wound area (cm <sup>2</sup> )	Percent healed (%)
1	2	Venous ulcer with fistula	Right dorsal foot	61	7	3.1	0.7	77
	3	Venous ulcer	Left dorsal foot	11	1	1.4	0	100
4	4	Pressure ulcer	Right heel	36	5	3.6	0.6	82
6	6	Pressure ulcer	Left heel	49	7	4.7	0	100
	8	Pressure ulcer	Right heel	36	5	3.2	0	100
7	7	Venous ulcer	Right shin	7	1	2.8	0	100
8	9	Pressure ulcer	Sacrum	50	7	6.6	0	100
9	1	Tear wound	Left Shin	21	1	28.1	0	100
10	5	Amputation	Middle finger tip of right hand	19	1	0.9	0	100

for 31 clots; the other 4 sessions required 2 attempts.

All 35 application sessions resulted in the successful clot formation to adequately be placed over the wounds. Clot formation occurred for all applications faster than the 10 minutes initially required by the procedure. Most of the clots formed within 7 minutes, although some required up to 9 minutes.

**Healing rates and outcomes.** The clinical outcomes of wounds treated with the whole blood clot matrix are summarized in Table 3. Complete healing was achieved in 7 of 9 wounds (78%). A before and after example of complete healing in a pressure ulcer (wound No. 9) on the sacrum of a bedridden, 90-year-old female patient (patient No. 8) with Huntington's disease, severe dementia, chronic anemia, and lipidemia is provided in Figures 4A and 4B. Complete closure was achieved after 50 days with 7 whole blood clot matrix applications (Table 3).

In Figure 5A, a pressure ulcer (wound No. 6) on the left heel of a bedridden, 90-year-old male patient (patient No. 6) with similar multiple comorbidities is shown measuring at 4.7 cm<sup>2</sup> prior to the clot matrix treatment. In Figure 5B, the ulcer is shown completely healed after 49 days with 7 applications (Table 3).

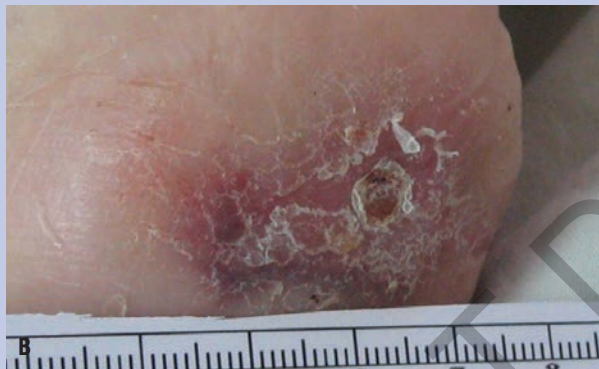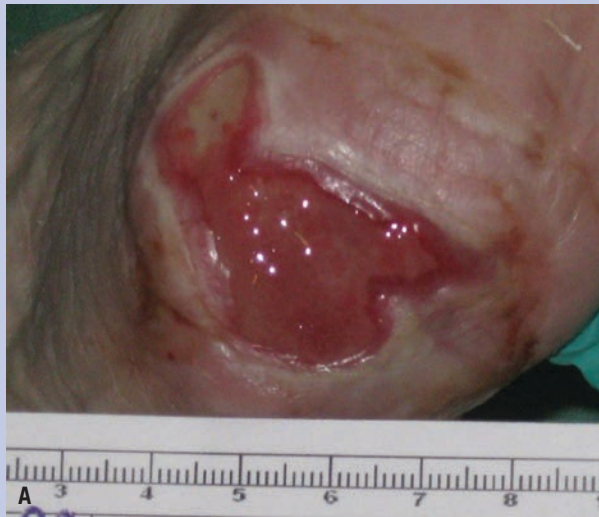The 2 wounds that did not achieve complete closure were partially closed: wound No. 2 was 77% closed, and

wound No. 4 was 82% closed. Two patients with diabetes had 3 chronic wounds: 2 stage III pressure ulcers on each of patient No. 6's heels and a venous ulcer on the right shin of patient No. 7. The healing of these chronic ulcers in these patients with diabetes was similar to the healing in patients without diabetes. The 2 wounds that did not achieve full closure are discussed in further detail in the next sections.

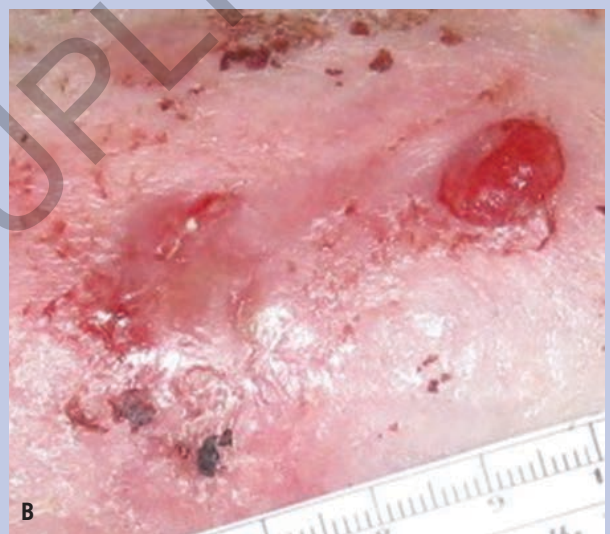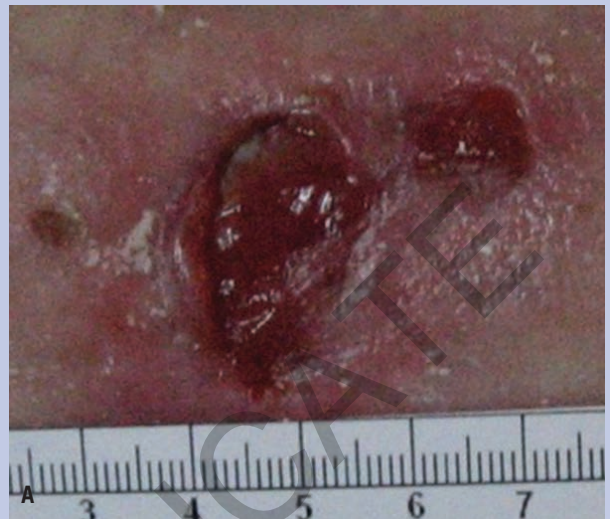Most treatment periods lasted 7 to 61 days, with 1 to 7 applications required (Table 3). Treatment lasted 7 to 50 days on wounds with complete closure. Only a single clot matrix application was needed in 4 wounds (ie, 2 venous ulcers, a tear wound, and a middle finger tip amputation). The range of applications was 1-7 with a mean of 3.9 applications per wound on average every 8.3 days.

Two days after each application, only the primary and secondary dressings were removed and the whole blood clot matrix was monitored. In all cases, the clot remained attached to the wound in the original location and no odor was detected from the clot. There were no signs of any adverse reaction in the wound and in the periwound area. Seven of the 9 wounds had moderate to heavy exudate observed during the first whole blood clot matrix application.

*Patient No. 1, wound No. 2 and No. 3.* An 88-year-



**Figure 5.** (A) Patient No. 6, wound No. 6: A pressure ulcer on the patient's left heel with an initial area of 4.7 cm<sup>2</sup>; and (B) the same patient and wound with complete healing achieved on day 49 after 7 whole blood clot matrix applications.



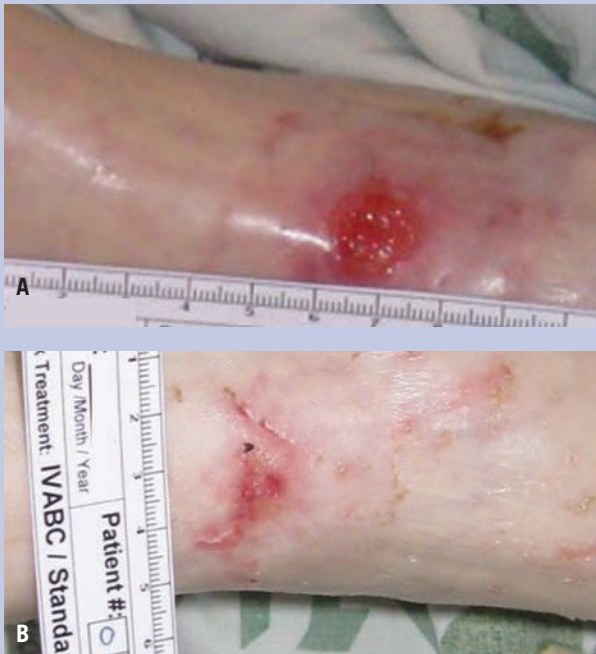**Figure 6.** (A) Patient No. 1, wound No. 2: A venous ulcer on the patient's right foot with an exuding fistula beside the ulcer and an initial area of 3.1 cm<sup>2</sup>; and (B) the same patient and wound with complete healing achieved on day 61 after 7 whole blood clot matrix applications. The fistula remained unhealed and the final wound area was 0.7 cm<sup>2</sup> (77% closure).

old female patient presented with 2 venous ulcers of 3 months duration each, 1 on the dorsal side of the right foot (wound No. 2; Figure 6A) and another on the dorsal side of the left foot (wound No. 3; Figure 7A). The patient was also diagnosed with a 1 cm long, exuding fistula next to wound No. 2 (Figure 6A), which was also treated with the product. The patient was bedridden with serious comorbidities, including paralysis on the right side of her body following a stroke, hypertension, malnutrition, severe dementia, hypoalbuminemia, and chronic anemia. The ulcer on the right foot was more than twice the area of the ulcer on the left foot (3.1 cm<sup>2</sup> and 1.4 cm<sup>2</sup>, respectively). The smaller ulcer healed after 11 days with a single application of the whole blood clot matrix (Figure 7B). The fistula required a surgical procedure and was then

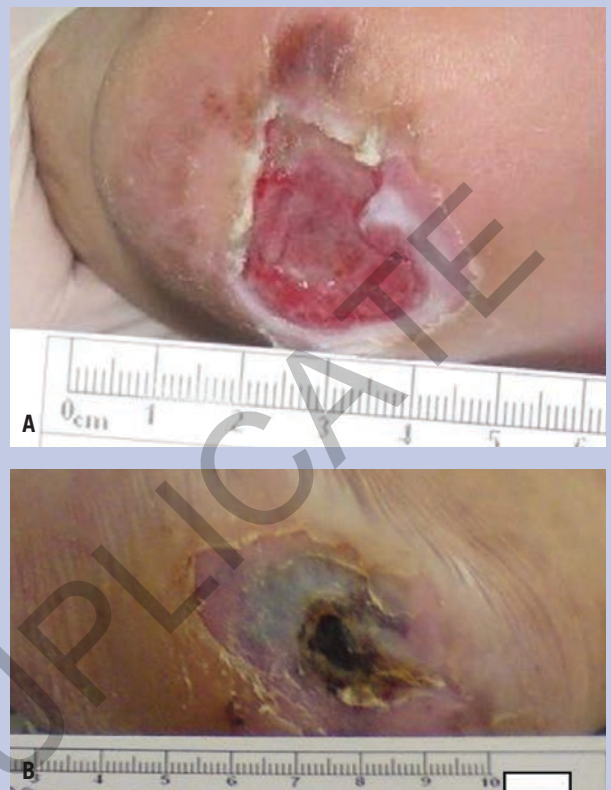covered with the same clot matrix covering the venous ulcer for the study duration. Although the venous ulcer was healed with complete closure after 61 days with 7 clot matrix applications, the fistula did not heal (Figure 6B). Thus, the final wound area was 0.7 cm<sup>2</sup>, implying the wound was only 77% closed.

*Patient No. 4, wound No. 4.* A 48-year-old female patient had a stage III pressure ulcer on her right heel for 3 months with concurrent multiple sclerosis, severe de-





**Figure 7.** (A) Patient No. 1, wound No. 3: A venous ulcer on the patient's left foot with an initial area of 1.4 cm<sup>2</sup>; and (B) the same patient and wound with complete healing achieved on day 11 after 1 whole blood clot matrix application.



**Figure 8.** (A) Patient No. 4, wound No. 4: A pressure ulcer on the patient's right heel with an initial area of 3.6cm<sup>2</sup> before treatment with the whole blood clot matrix; and (B) the same patient and wound on day 36 with 82% closure (final area: 0.64 cm<sup>2</sup>). Treatment was terminated after 5 applications of the whole blood clot matrix because the wound reopened following poor offloading that resulted in recurrent direct pressure on the wound.

mentia, and obesity. The initial wound area was 3.6 cm<sup>2</sup> (Figure 8A). Treatment was stopped after 82% closure was achieved with a final wound area of 0.6 cm<sup>2</sup> recorded on day 36, because the wound deteriorated and increased in size (Figure 8B) as a result of recurrent direct pressure exerted on the wound from a less than optimal offloading procedure. On day 40, an adverse event unrelated to the whole blood clot matrix occurred, when the nurse let the wound lay directly on the metal bed side, which caused mechanical trauma to the wound. The wound area increased to its size at enrollment.

There were no other adverse events reported in any of the patients during the course of the study.

## Discussion

The whole blood clot matrix was effective and safe in treating a small sample of patients with chronic and acute wounds that varied in severity and duration. Most patients had multiple serious comorbidities and were bedridden, which could have hindered the healing process. Yet, in spite of the poor health status of the participating patients, 78% of the wounds healed and healing outcomes were generally similar among all cases. There were

no differences in healing outcomes between patients with diabetes and patients without diabetes. Although a fistula alongside a venous ulcer did not heal (patient No. 1, wound No.2) and 1 adverse event occurred from poor offloading that caused a pressure ulcer to deteriorate (wound No.4), neither complication was related to the whole blood clot matrix.

This was the first clinical study evaluation of the matrix. In 7 wounds, the clot matrix was replaced every 6-9 days. In 1 wound (patient No. 7, wound No.7), a single application was sufficient for 7 days, while in 3 wounds (patient No. 9, wound No.1; patient No. 10, wound No. 5; and patient No. 1, wound No. 3) a single application was used for 11-21 days. The decision for replacing the product in 5 wounds was based on both the need to control and

document the wound healing process in reasonable time intervals for investigational purposes and based on the known active timeframe of the whole blood clot matrix. In wounds that had only a single application of the clot matrix applied for more than 9 days, the care provider decided whether or not the product was adequately integrated into the healing tissue of the wound bed, which was determined when the matrix did not detach from the wound upon being gently touched. The care provider further decided that removing the whole blood clot matrix might have interrupted the healing process. The fact that 2 of these wounds (patient No. 9, wound No. 1; and patient No. 10, wound No. 5) were acute wounds might explain why the matrix so strongly adhered to the wound. The authors believe that in some cases, the clot can remain on the wound for up to 2 weeks uninterrupted while the wound edges are regularly monitored for potential adverse events; however, the efficacy of the procedure with 2-week intervals needs further investigation.

When tissue is injured, blood vessel disruption and extravasation of blood constituents occur.<sup>5,7,9,11,15</sup> The inability to reestablish a blood supply to the wound can delay healing and lead to a chronic wound.<sup>15</sup> The whole blood clot matrix addresses the urgent need to reestablish hemostasis and kick start the other healing phases through the creation of an in vitro blood clot. The blood clot is the best natural wound healing agent with essential roles and functions in every stage of the healing process.<sup>5-11</sup> Early on in wound repair, the blood clot reestablishes hemostasis and protects the wound with its fibrin scaffold, a provisional matrix that mediates inflammation by promoting angiogenesis and hosting the essential cytokines and growth factor needed to transition the healing process from inflammation and proliferation to repair. The dissolution of the clot reveals the repaired tissue.

The provisional whole blood clot matrix kit provides a practical tool for creating in vitro blood clots in a safe, consistent, and controlled manner. The materials used in the kit are citrate, calcium, and kaolin, all of which are known moderators of coagulation timing. These materials do not affect the cascade of events of the coagulation process or the final blood clot formation; moreover, they are all frequently used in a medical setting.<sup>19-26</sup> The whole blood clot matrix, however, uses the patient's own coagulated blood as an autologous wound dressing, which minimizes the risk for immunorejection.

A blood clot is fragile and delicate. For use of the clot as a provisional wound matrix, the kit includes a specialized clotting tray which is used to control the shape

and dimensions of the final clot, adjusted to the specific wound dimensions. The whole blood clot matrix kit includes a sterile gauze pad as a supportive scaffold of the fragile blood clot, which is to be embedded into the clot during the coagulation process. The clot with the embedded gauze is robust enough to be transferred from the clotting tray to the wound in a controlled and safe manner, enabling further shaping of the clot and anchoring to the wound and the surrounding skin.

The major limitation of this study was the very small sample size; however, the 7 participating patients represented a wide variety of real-world clinical care scenarios, and most of the patients had serious comorbidities that presented further challenges to their care. A diverse variety of chronic wounds, as well as acute wounds, were treated in this study. The long-term safety of this product could not be determined in some patients whose wounds healed quickly after only 1 application. A large clinical trial with a longer follow-up period is needed to confirm the safety and efficacy of the whole blood clot matrix.

## Conclusions

This small pilot study demonstrated that a care provider can effectively, consistently, and safely prepare an in vitro blood clot using the whole blood clot matrix kit at the point of care. A healing process was observed in all 9 wounds treated with the clot matrix, the majority of which achieved complete healing. Treatment with the matrix did not delay healing, and no adverse events were observed during the study. Thus, the study demonstrated that the application of the autologous blood clots to wounds is safe for patients with chronic wounds and with multiple serious comorbidities. A larger clinical trial is needed to confirm the findings in this study. The long-term safety of the product is under investigation for treatment of diabetic foot ulcers.

## References

1. You HJ, Han SK. Cell therapy for wound healing. *J Korean Med Sci.* 2014;29(3):311-319.
2. Diegelmann RF, Evans MC. Wound healing: an overview of acute, fibrotic and delayed healing. *Front Biosci.* 2004;9:283-289.
3. Shah JM, Omar E, Pai DR, Sood S. Cellular events and biomarkers of wound healing. *Indian J Plastic Surg.* 2012;45(2):220-228.
4. Baum CL, Arpey CJ. Normal cutaneous wound healing: clinical correlation with cellular and molecular events. *Dermatol Surg.* 2005;31(6):674-686.

5. Singer AJ, Clark RA. Cutaneous wound healing. *N Engl J Med*. 1999;341(10):738–746.
6. Razzell W, Wood W, Martin P. Swatting flies: modelling wound healing and inflammation in *Drosophila*. *Dis Model Mech*. 2011;4:569–574.
7. Clark RA. Fibrin and wound healing. *Ann NY Acad Sci*. 2001;936:355–367.
8. Miloro M, Ghali E, Larsen P, Waite P, eds. *Peterson's Principles of Oral and Maxillofacial Surgery*. 2nd ed. Hamilton, Ontario: BC Decker Inc; 2004.
9. Laurens N, Koolwijk P, de Maat MP. Fibrin structure and wound healing. *J Thromb Haemost*. 2006;4(5):932–939.
10. Tonnesen MG, Feng X, Clark RA. Angiogenesis in wound healing. *J Invest Dermatol Symp Proc*. 2000;5(1):40–46.
11. Clark RAF, ed. *The Molecular and Cellular Biology of Wound Repair. Second Edition*. Norwell, MA: Kluwer Academic Publishers; 1996.
12. Mustoe TA, O'Shaughnessy K, Kloeters O. Chronic wound pathogenesis and current treatment strategies: a unifying hypothesis. *Plast Reconstr Surg*. 2006;117(7 Suppl):35S–41S.
13. Guo S, Dipietro LA. Factors affecting wound healing. *J Dent Res*. 2010;89(3):219–229.
14. Lau J, Tatsioni A, Balk E, et al. Usual Care in the Management of Chronic Wounds: A Review of the Recent Literature [Internet]. Rockville, MD: Agency for Healthcare Research and Quality (US); 2005.
15. Demidova-Rice TN, Durham JT, Herman IM. Wound healing angiogenesis: innovations and challenges in acute and chronic wound healing. *Adv Wound Care (New Rochelle)*. 2012;1(1):17–22.
16. Winter GD. Formation of the scab and the rate of epithelization of superficial wounds in the skin of the young domestic pig [letters to nature]. *Nature*. 1962;193:293–294.
17. Turner NJ, Badylak SF. The use of biologic scaffolds in the treatment of chronic nonhealing wounds. *Adv Wound Care (New Rochelle)*. 2015;4(8):490–500.
18. Supp DM, Boyce ST. Engineered skin substitutes: practices and potentials. *Clin Dermatol*. 2005;23(4):403–412.
19. Martin MJ. Editorial to accompany "A pilot study of the use of kaolin-impregnated gauze (Combat Gauze) for packing high-grade hepatic injuries in a hypothermic coagulopathic swine model." *J Surg Res*. 2014;186(1):116–118.
20. Sena MJ, Douglas G, Gerlach T, et al. A pilot study of the use of kaolin-impregnated gauze (Combat Gauze) for packing high-grade hepatic injuries in a hypothermic coagulopathic swine model. *J Surg Res*. 2013;183(2):704–709.
21. Kheirabadi BS, Scherer MR, Estep JS, Dubick MA, Holcomb JB. Determination of efficacy of new hemostatic dressings in a model of extremity arterial hemorrhage in swine. *J Trauma*. 2009;67(3):450–459.
22. Committee on Tactical Combat Casualty Care. Tactical Combat and Casualty Care Guidelines. 2014. [www.itstactical.com/medcom/tccc-medcom/2014-tccc-tactical-combat-casualty-care-guidelines/](http://www.itstactical.com/medcom/tccc-medcom/2014-tccc-tactical-combat-casualty-care-guidelines/). Accessed August 24, 2016.
23. Ran Y, Hadad E, Daher S, et al. QuikClot Combat Gauze use for hemorrhage control in military trauma: January 2009 Israel Defense Experience in the Gaza Strip—a preliminary report of 14 cases. *Prehosp Disaster Med*. 2010;25(6):584–588.
24. Patel SA, Martin M, Chamales I. Vaginal hemorrhage from transobturator sling controlled with QuikClot combat gauze. *Mil Med*. 2012;177(8):997–998.
25. Bates SM, Weitz JI. Coagulation assays. *Circulation*. 2005;112(4):e53–e60.
26. The National Pressure Ulcer Advisory Panel, European Pressure Ulcer Advisory Panel, Pan Pacific Pressure Injury Alliance. Prevention and Treatment of Pressure Ulcers: Quick Reference Guide. Emily Haesler, ed. Cambridge Media: Osborne Park, Australia; 2014. <http://www.npuap.org/wp-content/uploads/2014/08/Quick-Reference-Guide-DIGITAL-NPUAP-EPUAP-PPPIA-Jan2016.pdf>. Accessed August 24, 2016.
27. LeBlanc K, Christensen D, Orsted HL, Keast DH. Best practice recommendations for the prevention and treatment of skin tears. *Wound Care Canada*. 2008;6(1):14–30.
28. Payne RL, Martin MC. Defining and classifying skin tears: need for a common language. *Ostomy Wound Manage*. 1993;39(5):16–20, 22–24, 26.
29. Medical Dictionary for Regulatory Activities (MedDRA). MedDRA Web-Based Browser. 2016. [tools.meddra.org/wbb/](http://tools.meddra.org/wbb/). Accessed August 24, 2016.