

An observational pilot study to collect safety and efficacy data on wound care using whole blood clot technology on hard-to-heal wounds

Authors:

Liezl Naude, Patricia Idensohn, Febe Bruwer, Georges Balenda, Magda Mulder, Maxim Gurevich, Moreno Matityahu, Yael Izakson, Ruhama Fridman and Dino Rech

This multi-centre observational pilot study explored the use of whole blood clot (WBC) therapy on hard-to-heal wounds where the phases of wound healing have been interrupted or stalled. Primary data from 29 patients were gathered from 10 pilot sites in South Africa and Israel. Prior to the application of WBC as an advanced technology, several other advanced wound care technologies, devices and wound care products were used in 48% of patients for more than 12 months, without achieving wound closure. An average of 65% reduction in wound size was achieved in 4 weeks in this pilot study, illustrating safety and efficacy for WBC application in hard-to-heal wounds.

Funding:

The research received no funding and was independently conducted.

Conflict of Interests:

One Eight Innovation Pty Ltd donated the products for use on the patients.

Chronic or non-healing wounds are defined as wounds that are slow to progress through the phases of healing, or display interrupted, or delayed healing due to intrinsic and extrinsic factors impacting on the wound and the individual (Sibbald et al, 2015; Woo et al, 2015; Woo et al, 2018). When the exclusion or correction of underlying pathologies have been addressed, the non-healing wound may suggest the presence of biofilm (International Wound Infection Institute, 2016). Managing the underlying pathologies of these wounds — which include diabetic ulcers, vascular ulcers (venous and arterial ulcers), pressure ulcers and malignancies — is essential (Frykberg and Banks, 2015; Sibbald et al, 2015; Aitken et al, 2019).

A hard-to-heal wound is a wound that has not healed by 40–50% after 4 weeks of standard care being provided, and alternative therapies should be considered with a referral to a wound care specialist or multidisciplinary team (Aitken et al, 2019). In this article, the umbrella term “hard-to-heal” is used for all chronic wounds or non-healing wounds.

Hard-to-heal wounds place a significant burden on the health system, patients and their families, as well as their circle of care (Zhao et al, 2016; Woo et al, 2018). They cause infections, pain, loss of function, high financial

costs and they often lead to amputations or sepsis. The incidence of chronic wounds has been increasing and is a silent epidemic, which impacts the quality of life of over 40 million people worldwide (Zhao et al, 2016). According to a systematic integrative review on the management of non-healable and maintenance wounds — hard-to-heal wounds, or those that stall over time, may benefit from an interprofessional team’s intervention, which may include reassessment and a change of treatment strategy to address the underlying cause of the wound (Boersema et al, 2021).

Wound healing physiology

The process by which cutaneous healing happens is very complex and is fundamentally dependent on a very well-orchestrated ‘symphony’ of events that would ultimately result in the restoration of the tissue deficit (Sibbald et al, 2011; Han and Ceilley, 2017). When the normal sequence of events is interrupted due to either intrinsic or extrinsic factors, this could result in a chronic, non-healing wound (Schultz et al, 2003; 2011; Boersema et al, 2021).

The repair process post-wounding is initiated by the process of haemostasis, followed by physiologically co-ordinated processes that includes inflammation, proliferation and remodelling (Young and McNaught, 2014). These

Liezl Naude is a Nurse Specialist & Educator in Advanced Wound Care, Eloquent Health & Wellness, Principle Lecturer Wound Care Eloquent Learning Health and Foundation of Professional Development, Pretoria, South Africa; Patricia Idensohn is an Advanced Wound Nurse Specialist, CliniCare Medical Centre, Balito, Principle lecturer Faculty of Health Sciences, University of Free State South Africa, Honorary Tutor School of Medicine, College of Biomedical and Life Sciences, Cardiff University, Wales, UK; Febe Bruwer is a Nurse Specialist in Advanced Wound Care, Nianwi Health Care, Johannesburg, South Africa, Vice President WHASA, South Africa; Georges Balenda is a General Surgeon and Clinical Manager at Tembisa Provincial Tertiary Hospital, Tembisa, South Africa; Magda Mulder is Head of the School of Nursing, University of the Free State, Bloemfontein, South Africa; Maxim Gurevich is a Orthopedic Surgeon, head of diabetic foot clinic in Hillel Yaffe Hospital, Hadera, Israel; Moreno Matityahu is a Orthopedic Surgeon, Moreno Clinic, Netanya, Israel; Yael Izakson is a Nurse Specialist in Advanced Wound Care, Izakson Clinic, Ramat Gan, Israel; Ruhama Fridman is a Nurse Specialist in Rehabilitation, deputy head nurse in rehabilitation Hospital, Tel Hashomer, Ramat-Gan, Israel; Dino Rech is a physician and the Regional Chief Operating Officer: Health Programmes, The Aurum Institute, Johannesburg South Africa.

processes involve an intricate balance between vascular and cellular events, which are initiated by chemicals, body cells and growth factors (GFs). The initial phases aim to prevent blood loss and prevent infection, in order for the wound to move into the proliferative or healing phase, and finally when epithelisation has happened for the scar to remodel and mature (Han and Ceilley, 2017).

Several barriers exist that could influence this process and prevent wound healing. These barriers include infection, hypoxia, underlying diseases, such as diabetes and several other pathophysiological phenomena, which result in prolonged inflammation, chronic infection, cell senescence and a failure to heal (Han and Ceilley, 2017). Other barriers include health system challenges, such as lack of resource skills and expertise (Boersema et al, 2021).

Comparator advanced technologies and devices in chronic wound care

The development of advanced wound technologies and devices are increasing, providing clinicians with varied treatment options for hard-to-heal wounds. The wound care practitioner must be knowledgeable regarding the patient population for which the specific technology or device is proposed (Anderson et al, 2016). The various comparator advanced technologies used in WBC application are described below:

Autologous platelet rich plasma (PRP)

PRP is composed of high concentrations of GFs and fibrin, which are responsible for blood clotting. Due to the low quality of evidence and minimal randomised controlled trials (RCTs) available, it is undecided whether PRP impacts on the healing of chronic wounds other than diabetic foot ulcers (DFUs), which has only been concluded in two RCTs, according to a Cochrane review in 2016 (Martinez-Zapata et al, 2016).

Amnion/chorion membrane (AM)

GFs, cytokines and stem cells, which advance healing, inhibit infection and stimulate regeneration, are abundant in amnion taken from human placenta (Haugh et al, 2017). AM promotes epithelialisation in pressure ulcers in conjunction with standard of care (Dehghani et al, 2017). Serena et al (2019) reported significant improved healing of venous leg ulcers (VLUs) treated with AM and compression, when compared with the use of compression alone. Systematic reviews and meta-analyses

indicate accelerated healing rates of DFUs with the application of AM (Haugh et al, 2017; Su et al, 2020).

Hyperbaric oxygen therapy (HBOT)

In a Cochrane review of HBOT for chronic wounds, Kranke et al (2015) found no research on pressure injuries or arterial ulcers eligible for inclusion. Further, they concluded short-term improvement in the healing of DFUs by 6 weeks, when HBOT was utilised as an adjunct to standard wound care (SWC). A recent multicentre RCT of DFU patients with concomitant limb ischaemia concluded no improvement in wound healing when comparing HBOT to SWC (Santema et al, 2018).

Growth factors (GFs)

The application of GFs on VLU may reduce the wound area significantly, but complete healing is uncertain (Lee et al, 2018; Carvalho et al, 2019). RCTs with a high risk of bias concluded GFs applied to DFUs may increase the possibility of complete healing, although the safety reports of GFs remain unclear (Martí-Carvajal et al, 2015).

Negative pressure wound therapy (NPWT)

NPWT benefits different types of wounds differently, by enhancing granulation formulation, controlling exudate, effecting perfusion and reducing bacterial load (Lalezari et al, 2017). Despite successful results proven by several studies (Sadat et al, 2008; Wynn and Freeman, 2019; Andonegi et al, 2020) some reviews suggest more robust studies are required to support the extensive use of NPWT (Webster et al, 2014; Anghel and Kim, 2016; Andonegi et al, 2020). Olaiya et al (2020) warn healthcare consumers and patients regarding the interpretation of results of NPWT non-Cochrane systematic reviews, due to inadequate reporting, conduct and critical appraisal.

Methods

Ethical approval

The study was granted ethical approval by the University of Witwatersrand Johannesburg Human Research Ethics Committee (Medical) clearance certificate no M201082. Ethics approval was not required for the observational pilot in Israel as WBC is an approved wound care product in the country.

Study selection

Ten observational pilot sites were chosen from South Africa and from Israel [Table 1].

Table 1. Study selection criteria.

Population inclusion criteria	Persons 18 years of age and older who has a chronic or hard-to-heal wound. Agrees to the use of their health data, including photographs for analysis and publication as per ethics approval. Participant must be able to read and understand English.
Population exclusion criteria	Active osteomyelitis. Inability to draw blood for the whole blood clot (WBC) procedure.
Comparator Advanced Technologies	Autologous platelet rich plasma (PRP) Amnion/chorion membrane (AM) Hyperbaric oxygen therapy (HBO) Growth factors (GFs) Negative pressure wound therapy (NPWT)
South African pilot sites	5
Israel pilot sites	5
Population total	29
Intervention	The application of WBC using the ActiGraft RedDress kit as Advanced Technology
Study design	Observational pilot study
Data collection	Informed consent Baseline demographics Medical health history Wound history Baseline wound sizes Wound care Wound reduction week 4 and week 12
Outcome	To evaluate the safety and efficacy of WBC, and to measure wound reduction at week 4 and week 12

Both sites used Conformité Européenne (CE) and Food and Drug Administration (FDA) approved WBC (Actigraft) for the treatment of hard-to-heal wounds.

Description of WBC procedure used as intervention in the observational study

Unlike various blood-derived products, such as PRP, macrophages, GFs and others, the WBC contains all the whole blood cellular content and does not undergo separation, manipulation or augmentation. It is, however, like a natural WBC (Serena et al, 2019; Wahab et al, 2020). With WBC, blood is mixed with kaolin to accelerate the clot formation (Serena et al, 2019; Kitchens et al, 2020). This treatment can also be used to protect the wound and to facilitate the wound healing process (Serena et al, 2019).

WBC is applied topically for the management of exuding cutaneous wounds. During the preparation of WBC, 15 ml of blood is drawn into sterile Acid Citrate Dextrose adenine (ACDA) vacuum tubes. The citrated blood is then gently mixed with a suspension of calcium gluconate and kaolin powder, and the coagulating blood is placed in a sterile

coagulation mould, containing cotton gauze, to coagulate for 8 minutes. After 8 minutes, the WBC is placed on a wound and dressed with a secondary sterile non-adherent dressing. All WBC elements and reagents are disposed of after a single use of the kit. The procedure may be repeated after 7 days.

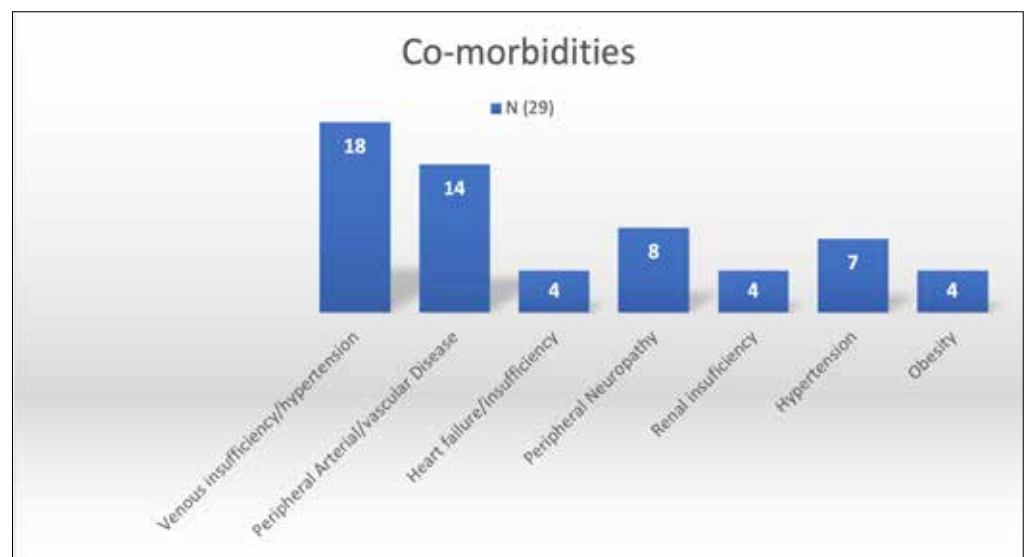
Once applied to the wound, the WBC will initiate an acute wound healing mechanism by releasing bio-signals into the tissue. During the inflammation phase, white blood cells and macrophages enter the wound to destroy bacteria and take away debris. The WBC creates a fibrin scaffold that is a protective, provisional extracellular matrix (ECM) containing cytokines and GFs that facilitate tissue repair. During the proliferation stage, the WBC recruits endothelial cells and fibroblasts to synthesise a permanent ECM. At this stage, the focus is on filling and covering the wound.

Lastly, within the remodelling phase, the blood clot dries out and becomes a protective scab. Under the scab, the tissue remodelling takes place undisturbed. The fibrin is then replaced by fibronectin and hyaluronan. The scab then falls off to reveal a collagenous scar [Figure 1].

Figure 1. Whole blood clot application procedure.

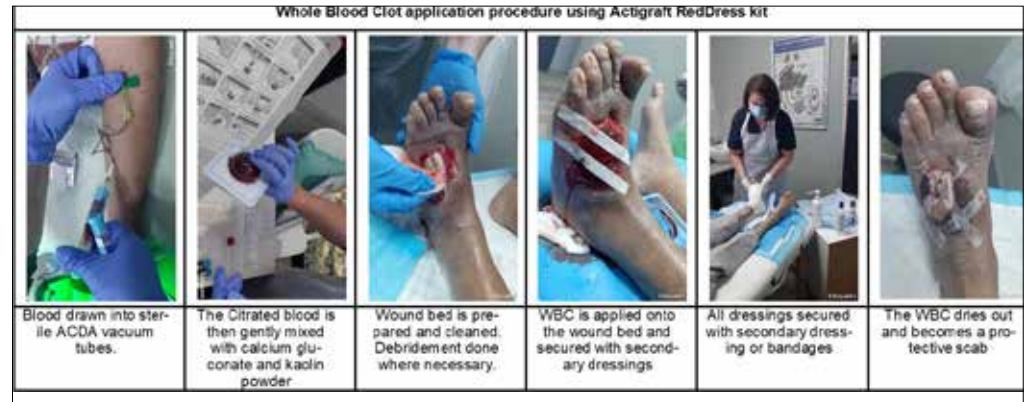

Figure 2. Patient comorbidities.



Data analysis

Data were collected according to the study criteria approved by the Ethics Committee. This was carried out between January 29, 2020 and January 31, 2021 and between July 12, 2020 and December 28, 2020 in Israel. A total number of 17 patients were included from five pilot sites in South Africa, concluded from both public and private health sector; and a total number of 12 patients were included from the five pilot sites in Israel.

Baseline data were collected at the first patient visit and included confirmation that all inclusion criteria was met, informed consent obtained, baseline demographic information, full medical history, ulcer or wound profile, history, assessment and treatment. At all subsequent treatment visits, data on the ulcer or wound assessment and treatment was collected and photographs of the wound taken.

The primary data captured from the pilot sites included wound size reduction at 4 weeks and at 12 weeks, and at last observation.

Results

Demographics

Three-quarters (75%) of patients were between the ages of 61 years and 80 years, with a further 7% over 80 years old. No patients were under the age of 40 years. Just over half (55%) of patients were female and 44% were male.

Health and comorbidities

Around two-thirds (67%) of patients never smoked, 22% were former smokers and 11% were current smokers. Fifty-five percent (55%) of patients were type 2 people with diabetes and 17% were type 1 people with diabetes. *Figure 2* is a summary of comorbidities recorded; 18 patients had venous insufficiency/hypertension, while 14 patients recorded peripheral arterial disease. These findings are in line with the global prevalence mentioned in the systematic review by Martinengo et al (2019).

Wound type

Forty-two percent (42%) of patients had vascular ulcers and 31% of patients had diabetic foot ulcerations. Seven percent (7%) of surgical

Figure 3. Wound type.

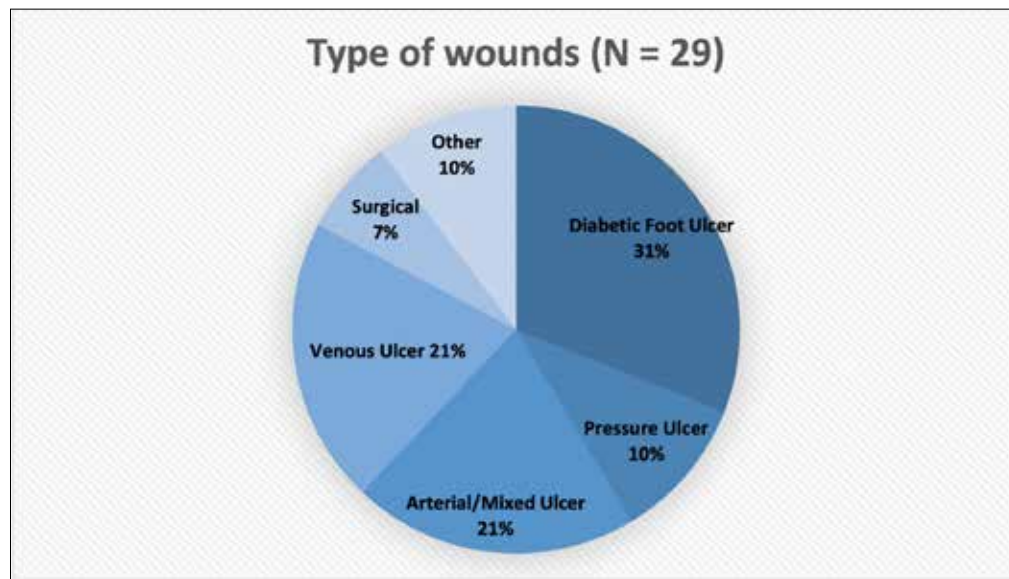
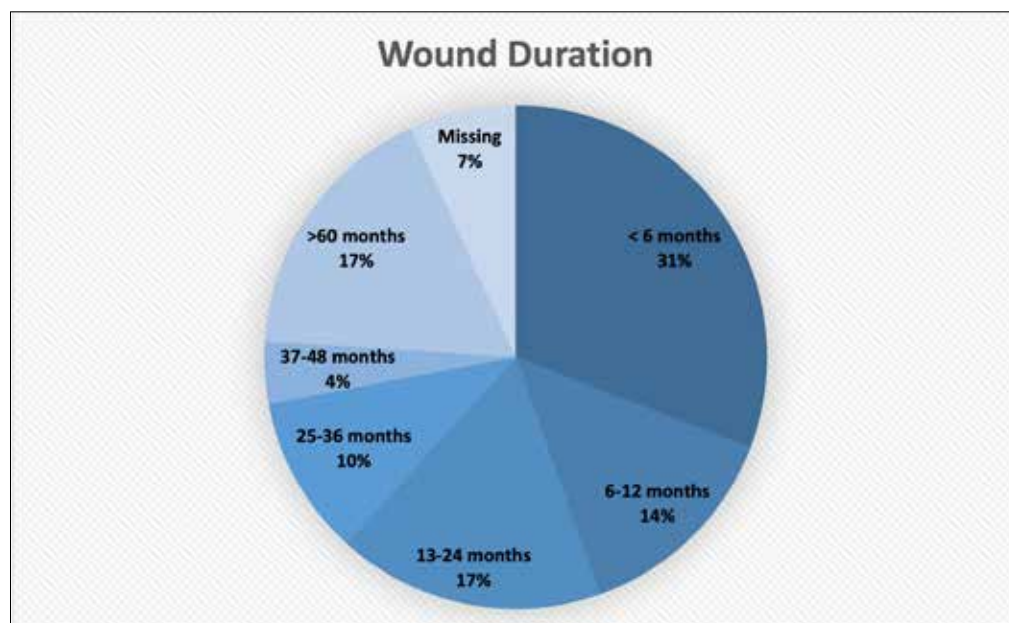

Figure 4. Wound duration.



wounds developed due to surgical site infections postoperatively, and 10% of patients had pressure ulcers [Figure 3].

Wound location

Almost all (97%) hard-to-heal wounds were recorded on the lower leg; 59% of all ulcerations occurred on the foot and heel area. The remaining 3% was a post-surgical wound on the thigh area.

Wound duration

Thirty-one percent (31%) of patients had their wounds for less than 6 months, while 17% of patient had chronic wounds for longer than 60 months. Over half (55%) of all patients had been struggling with hard-to-heal wounds for longer than 12 months, with the average wound

duration of 24 months in total. Summary of wound duration in total is depicted in Figure 4.

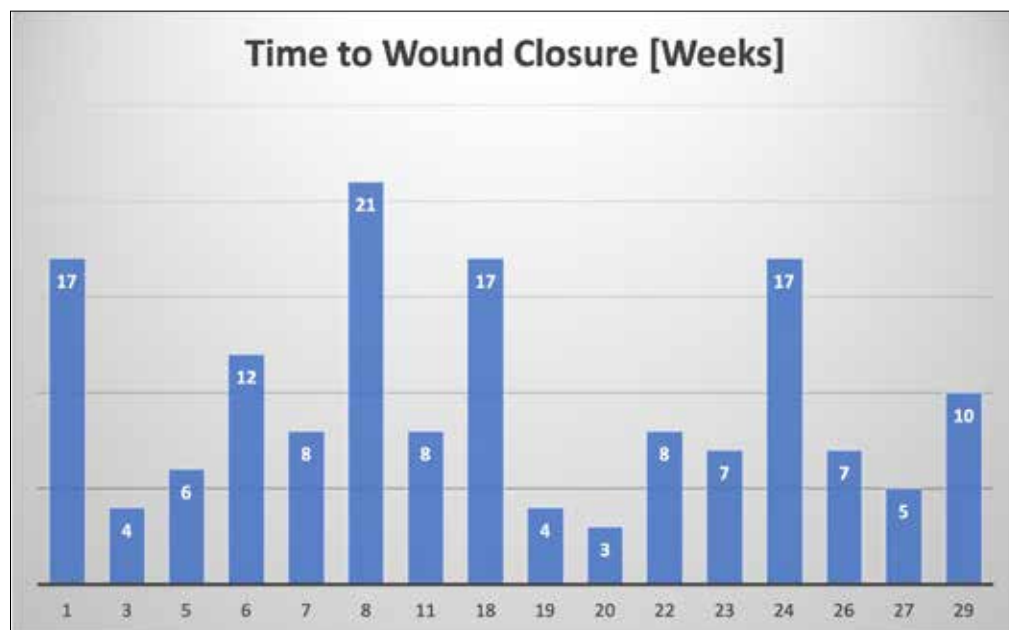Previous wound care treatments

Seventy-four percent of patients had previously been treated with more than one negative pressure wound therapy (NPWT) dressing application, 7% were treated with honey, 3% had a split skin graft.

Wound reduction at weeks 4, 12 and last observation

The reality of the COVID-19 worldwide pandemic, with subsequent lockdown measures applied in both participating countries during 2020 and 2021, impacted the data gathering process and resulted in a delayed treatment period. As such, several patients were lost to

Figure 5. Time to wound closure (in weeks).



follow-up (LTFU) during the observation periods. The time between baseline and last observation varied among participants depending on the time taken for wound closure, as well as the cut off point for the observation study.

Table 2 illustrates the wound measurements and decrease in size during the observational period.

Two patients were LTFU after week 3, patient 13 showed a wound reduction of 24% and patient 14 showed a wound reduction of 73% at their last observation.

By week 4, three patients reached 100% closure (Patient 3, 19 and 21). Minimum percentage in wound reduction was 19% after 4 weeks. Average percentage wound reduction recorded at 4 weeks was 65%.

Six patients were LTFU by week 12, with no further data collection available for one patient (Patient 2) after week 12. Week 12 had 17 remaining patients within the study; eight patients reached 100% closure at week 12 (patients 5, 6, 7, 22, 23, 26, 27, 29). Two patients were not observed beyond 12 weeks (Patient 17 and 25) — both of whom had reached 80% area reduction at the last observation. The average percentage area reduction by week 12 was 94%.

Beyond week 12, a further eight patients (Patient 1, 2, 8, 11, 18, 20, 24 and 28) required treatment and follow-up. Three of these patients (18, 20 and 24) reached full wound closure by the last observation, while the remaining five patients reached between 93% and 97% area reduction when they were last observed. Last observation for these remaining five patients was due to the cutoff point of the study in South

Africa. The average percentage wound reduction at the last visit was 99% [Table 2].

Time to wound closure

Figure 5 below shows the time to wound closure (in weeks) for all those patients that completed the treatment and observation visits. Sixteen patients followed and completed the treatment until full wound closure; 12 did not require the full first 12 weeks and one reached full wound closure at the 12th application. The remaining four patients reached full wound closure between application 17 (three patients) and application 21 (one patient).

WBC case examples

Case 1 (Patient 1): mixed vascular ulcer

The patient is an 80-year-old female with a vascular mixed ulceration on the right leg medial. She is a former smoker and had a hard-to-heal wound for longer than 12 months. Numerous advanced wound care products were used during this period, which resulted in mostly false responses to the previous treatments. Adjunctive therapies used were Red light and Near Infrared (NIR) light therapy, as well as moderate compression bandaging. Baseline measurement was 13.72cm².

The patient suffered severe cardiac failure in week 4 amid the COVID-19 pandemic, which resulted in delayed treatment for the cardiac failure and subsequent bilateral limb oedema.

Outcome after last observation (14 weeks)

Despite the setback, wound size recorded at last visit was 0.17cm², and a total reduction

Table 2. Wound size at baseline, 4 weeks, 12 weeks and endline.

Patient #	Baseline measurements (cm ²)	Week 4 size reduction %	Week 12 size reduction %	Last observation reduction %	Last visit wound measurements (cm ²)
1	13.74	66%	86%	95%	0.71
2	8.84	73%	-	93%	0.63
3	1.06	100%	100%	100%	0
4	23.76	40%	LTFU*		6.87
5	13.19	88%	100%	100%	0
6	10.84	86%	100%	100%	0
7	2.17	28%	100%	100%	0
8	54.19	41%	87%	97%	1.57
9	102.10	77%	LTFU*		No data
10	43.20	49%	LTFU*		5.65
11	13.74	66%	86%	95%	0.71
12	119.38	37%	LTFU*		43.98
13	63.00	LTFU*	LTFU*		47.60
14	8.40	LTFU*	LTFU*		2.16
15	26.60	19%	LTFU*		8.60
16	40.50	44%	LTFU*		22.75
17	39.27	65%	80%	LTFU*	7.85
18	247.00	50%	94%	100%	0
19	2.50	100%	100%	100%	0
20	49.00	69%	89%	100%	0
21	18.50	100%	100%	100%	0.70
22	38.50	88%	100%	100%	0.20
23	7.00	76%	100%	100%	0
24	9.50	43%	84%	100%	0
25	15.00	80%	80%	LTFU*	3
26	2.25	89%	100%	100%	0
27	2.00	80%	100%	100%	0
28	57.00	53%	91%	96%	2
29	37.00	54%	100%	100%	0
Average		65%	94%	99%	

*Lost to follow-up

of 13.55cm². The patient had a decrease in pain and overall skin quality improved. No adverse effects were observed related to the WBC application.

Case 2 (Patient 8): diabetic foot ulcer (DFU)

The patient is a 65-year-old male patient with type 2 diabetes and suffered a Texas Grade 3C DFU on his left forefoot that had been present for 2 months. Prior to the application of WBC, sharp debridement was done to remove the eschar and medical grade honey was used to facilitate enzymatic debridement. Baseline

application showed an exposed tendon with a sinus extending to the medial aspect of the first digit, with probe to bone (osteomyelitis was excluded) involvement. In this patient, WBC was used in conjunction with Red light and NIR light therapies. Prior to application of WBC, the patient was scheduled for amputation, wheelchair bound and had depression. Baseline measurement was 54.19cm².

Outcome at 4 weeks

Wound size recorded at last visit was 31.89cm². Wound reduction of 41% at week 4. Wound bed

Figure 6. Case photo summary.

Case	Baseline photo	Week 4	Week 12	Final Photo
Case 1 (Patient 1) Mixed vascular ulcer			Photo not available	
	Baseline (13.72cm ²)	Week 4		Week 14 (0.17cm ²) Total reduction 13.55cm ²
Case 2 (Patient 8) Diabetic foot ulcer				
	Baseline (54.19cm ²)	Week 4 (31.89cm ²)	Week 12 (6.87cm ²)	Week 20 (1.57cm ²) Total reduction of 52.62cm ²
Case 3 (Patient 18) Mixed vascular ulcer				
	Baseline (247.0cm ²) Medial view	Baseline (247.0cm ²) Later view	Week 12 (113.62m ²)	Week 17 healed Total reduction of 247.0cm ²

still exposed tendon, but healthy granulation tissue present with sinus still present extending to the medial aspect of the first digit.

Outcome at 12 weeks

Wound size recorded at week 12 was 6.87cm². Wound reduction of 97% at week 12. Wound bed still exposed tendon, but healthy granulation tissue present with sinus still present extending

to the medial aspect of the first digit. Exudate decreased and patient's mobility and quality of life improved.

Outcome last observation (20 weeks)

Wound size recorded at last visit was 1.57cm². Total reduction of 52.62cm². The patient was completely mobile and back at work. No adverse effects were observed related to the WBC

Figure 6. Case photo summary (Continued).

Case	Baseline photo	Week 4	Week 12	Final Photo
Case 4 (Patient 29) Diabetic patient with dehisced surgical wound				
	Baseline (37.0cm ²)	Week 3	Week 10	Week 12 healed Total reduction of 37.0cm ²
Case 5 (Patient 22) Diabetic patient with diabetic foot ulcer				
	Baseline (38.5cm ²)	Week 4	Week 6	Week 8 healed Total reduction of 38.5cm ²
Case 6 (Patient 6) Diabetic patient with venous leg ulcer				
	Baseline (10.84cm ²)	Week 6 (2.2cm ²)	Week 12 healed Total reduction of 10.84cm ²	Final photo

application. Wound care was continued with foam wound dressings done by the patient himself at home.

Case 3 (Patient 18): person with diabetes with a mixed vascular ulcer

The patient is an 87-year-old male with type 2 diabetes and a mixed vascular ulceration on the right leg medial and posterior calf site. The

patient has used numerous advanced wound dressings and treatment over the past 2 years, which failed to lead to wound closure. Baseline measurement was 247.0 cm².

Outcome at week 4, 12 and 17

The patient had a 50% reduction in wound size at week 4 and a 94% reduction in wound size at week 12. The patient had 16 WBC applications

on a weekly basis. Last observational visit showed complete wound closure with small areas of scab formation. No adverse effects were observed related to the WBC application.

Case 4 (Patient 29): person with diabetes with dehisced surgical wound post-transmetatarsal amputation

The patient is an 84-year-old female with type 2 diabetes who had a transmetatarsal amputation following a non-healing DFU. She developed surgical site infection postoperatively and has used numerous advanced wound dressings and treatment over a period of 8 weeks, which failed to lead to wound closure. The baseline measurement was 37.0 cm².

Outcome at week 4 and 10

The patient had a 54% reduction in wound size at week 4 and a 100% reduction in wound size at week 10. The patient had 10 WBC applications on a weekly basis. No adverse effects were observed related to the WBC application.

Case 5 (Patient 22): person with diabetes with a DFU

The patient is a 68-year-old female with type 2 diabetes with a non-healing diabetic foot ulcer on the plantar aspect of the left foot for a period of 96 months. Previous treatment included NPWT, PRP and advanced wound care dressings. The baseline measurement was 38.5 cm².

Outcome after last observation (8 weeks)

Wound bed was debrided and cleaned before every application of WBC. The patient had a 100% reduction in wound size at week 8 and eight WBC applications on a weekly basis. No adverse effects were observed related to the WBC application.

Case 6 (Patient 6): person with diabetes and venous leg ulceration

The patient is an 80-year-old female with type 2 diabetes and a non-healing venous leg on the right lateral side of her lower leg. Previous treatment included various advanced wound care dressings and compression bandaging. The patient's wound bed had stubborn fibrin with granulation tissue visible and epibole wound edges. Baseline measurement was 10.84 cm². Wound size at week 5 was 2.2 cm². The wound bed showed healthy granulation tissue with good epithelialisation. The patient had no pain.

Outcome after last observation (12 weeks)

The patient had a 100% reduction in wound

size at week 12. The wound bed was covered with epithelial tissue. No adverse effects were observed related to the WBC application.

Discussion

The aim of this observational pilot study, consisting of 29 patients from South Africa and Israel, was to evaluate the safety and efficacy of WBC. To achieve this, data were accumulated from 10 different pilot sites on patient demographics, patient health and wound history, smoking history, previous wound treatment history and wound type. Wound progress was measured by taking photographs and recording wound sizes at baseline, week 4, week 12 and last observation.

Eighty-two percent of patients were older than 61 years and 33% had a history of smoking. Forty-two percent of patients had vascular ulcers and 31% of patients had diabetic foot ulcerations. The 7% of surgical wounds developed due to surgical site infections postoperatively and 10% of patients had pressure ulcers. These percentages are very similar to global prevalence data (Martinengo et al, 2019).

Ninety-seven percent of all wounds described in the study occurred in the lower limb, even though the wound types varied. Patients' wounds in this observational pilot study represented complex hard-to-heal wounds that are often excluded in observational studies.

The average wound reduction by week 4 was 65%. The biggest challenge in this study was the LTFU at week 12. This can be contributed directly to the COVID-19 pandemic and the strict lockdown measures that were implemented. Despite this challenge, 16 patients (55%) achieved 100% wound closure, 12 by week 4 and an additional four between week 17 and 21. No adverse effects were described because of the WBC application.

Prior to the application of WBC as an advanced technology, several other advanced wound care technologies, devices and advanced wound care products were used in 55% of patients for more than 12 months, without achieving wound closure. In four of the described cases, not only did wound healing occur in hard-to-heal wounds, but a scheduled amputation was avoided.

Recommended wound size decrease rates in hard-to-heal wounds within 4 weeks is described as 30% according to Boersema et al (2021). The 65% decrease in wound size within 4 weeks suggests that the application of WBC technology changes the chronic nature of the hard-to-heal

wound into an acute wound healing trajectory significantly faster than what is suggested in the literature (Boersema et al, 2021).

Conclusions and recommendations

This study did not include cost analysis, but by comparing the wound duration before application to wound duration after application of WBC technology there is a clear decrease in treatment time and faster wound healing rate. It is recommended that a retrospective cost analysis study is done to demonstrate the economic impact of the use of WBC as an advanced therapy. The ability to achieve 100% wound closure in hard-to-heal wounds has a significant cost impact, by stopping ongoing weekly wound care costs. Providing a wound care treatment that can heal wounds over the course of 1 year and also prevent amputations will even have a greater cost impact.

Even though advanced wound care, such as compression bandaging, was done and advanced wound care technologies, such as PRP and NWPT, were applied these wounds failed to heal prior to the application of WBC. Even in a limited pilot study, with only 29 participants, the positive impact of wound closure in hard-to-heal wounds cannot be ignored. Fifty-five percent of the wounds that closed in this study were over 12 months duration. In several studies mentioned by Woo et al (2018), 79% of patients with DFUs reported an inability to maintain employment, secondary to decreased mobility and fear of someone inadvertently stepping on their affected foot. In another study, 42% of leg ulcer patients identified that their leg ulcers were a key factor in their decision to stop working ultimately affecting finances and out-of-pocket expenses.

This observational study has proven the safety to patient and efficacy of the WBC when applied on the appropriate patient and the appropriate hard-to-heal wound.

Based on our findings in this observational pilot study we recommend the following:

- Hard-to-heal wounds, or those that stall over time may benefit from an interprofessional team's intervention (Boersema et al, 2021) that include the application of advanced therapy, such as WBC (Serena et al, 2019)
- WBC as an advanced therapy is shown as safe and effective to apply in a wide variety of hard-to-heal wounds, such as DFUs, vascular ulcers, pressure ulcers and non-healing surgical site infections
- The series of case studies illustrates the efficacy of WBC application in a wide variety

of hard-to-heal wounds

- Healthcare systems and insurance companies should use WBC in hard-to-heal wounds to achieve complete healing and, thus, reduce the ongoing burden to the patient and associated costs. WINT

References

- Aitken SJ, Choy OS, Monaro S (2019) A qualitative study exploring patient concerns and values in chronic limb-threatening ischemia. *J Surg Res* 243: 289–300
- Anderson CA, Hare MA, Perdrizet GA (2016) Wound healing devices brief vignettes. *Adv Wound Care (New Rochelle)* 5(4): 185–90
- Andonegi M, Las Heras K, Santos-Vizcaino E et al (2020) Structure-properties relationship of chitosan/collagen films with potential for biomedical applications. *Carbohydr Polym* 237: 116159
- Anghel EL, Kim PJ (2016) Negative-pressure wound therapy: a comprehensive review of the evidence. *Plast Reconstr Surg* 138(3 Suppl): 129S–37S
- Boersema GC, Smart H, Giaquinto-Cilliers MG et al (2021) Management of nonhealable and maintenance wounds: a systematic integrative review and referral pathway. *Adv Skin Wound Care* 34(1): 11–22
- Carvalho MRD, Silveira IA, de Oliveira BGBR (2019) Treatment of venous ulcers with growth factors: systematic review and meta-analysis. *Rev Bras Enferm* 72(1): 200–10
- Dehghani M, Azarpira N, Karimi VM et al (2017) Grafting with cryopreserved amniotic membrane versus conservative wound care in treatment of pressure ulcers: a randomized clinical trial. *Bull Emerg Trauma* 5(4): 249–58
- Frykberg RG, Banks J (2015) Challenges in the treatment of chronic wounds. *Adv Wound Care (New Rochelle)* 4(9): 560–82
- Han G, Ceilley R (2017) Chronic wound healing: a review of current management and treatments. *Adv Ther* 34(3): 599–610
- Haugh AM, Witt JG, Hauch A et al (2017) Amnion membrane in diabetic foot wounds: a meta-analysis. *Plast Reconstr Surg Glob Open* 5(4): e1302
- International Wound Infection Institute (2016) *Wound Infection in Clinical Practice: Principles of Best Practice*. London: Wounds International. Available at: <https://bit.ly/2QaGiWw> (accessed 11.05.2021)
- Kitchens BP, Synder RJ, Cuffy CA (2020) A literature review of pharmacological agents to improve venous leg ulcer healing. *Wounds* 32(7): 195–207
- Kranke P, Bennett MH, Martyn Saint-James et al (2015) Hyperbaric oxygen therapy for chronic wounds. *Cochrane Database Syst Rev* 2015(6): CD004123
- Lalezari S, Lee CJ, Borovikova AA et al (2017) Deconstructing negative pressure wound therapy. *Int Wound J* 14(4): 649–57
- Lee Y, Phillips SA, Stacey MC (2018) The use of growth factors for the treatment of chronic venous leg ulcers: a systematic review and meta-analysis. *J Vasc Surg* 68(3): e88–e89
- Marti-Carvajal AJ, Gluud C, Nicola S et al (2015) Growth factors for treating diabetic foot ulcers. *Cochrane Database Syst Rev* (10): CD008548
- Martinengo L, Olsson M, Bajpai R et al (2019) Prevalence

- of chronic wounds in the general population: systematic review and meta-analysis of observational studies. *Ann Epidemiol* 29: 8–15
- Martinez-Zapata MJ, Marti-Carvajal AJ, Sola I et al (2016) Autologous platelet-rich plasma for treating chronic wounds. *Cochrane Database Syst Rev* (5): CD006899
- Olaiya OR, Huynh M, McRae MH (2020) Comment on: "Negative pressure wound therapy reduces wound breakdown and implant loss in prepectoral breast reconstruction. *Plast Reconstr Surg Glob Open* 8(6): e2908
- Sadat U, Chang G, Noorani A et al (2008) Efficacy of TNP on lower limb wounds: a meta-analysis. *J Wound Care* 17(1): 45–8
- Santema KT, Stoekenbroek RM, Koelemay MJ et al (2018) Hyperbaric oxygen therapy in the treatment of ischemic lower-extremity ulcers in patients with diabetes: results of the DAMO2CLES multicenter randomized clinical trial. *Diabetes Care* 41(1): 112–9
- Schultz GS, Sibbald RG, Falanga V et al (2003) Wound bed preparation: a systematic approach to wound management. *Wound Repair Regen* 11(Suppl 1): S1–S28
- Serena TE, Kushnir I, Kushnir A et al (2019) The safety of an autologous whole blood clot product applied to full thickness dermal wounds in a porcine model for up to 18 days. *Chronic Wound Care Management and Research* 6: 39–49
- Sibbald RG, Elliott JA, Ayello EA, Somayaji R (2015) Optimizing the moisture management tightrope with wound bed preparation. *Adv Skin Wound Care* 28(10): 466–76
- Sibbald RG, Goodman L, Woo KY et al (2011) Special considerations in wound bed preparation 2011: an update. *Adv Skin Wound Care* 24(9): 415–36; quiz 437–8
- Su YN, Zhao DY, Li YH et al (2020) Human amniotic membrane allograft, a novel treatment for chronic diabetic foot ulcers: A systematic review and meta-analysis of randomised controlled trials. *Int Wound J* 17(3): 753–64
- Wahab N, Lapucha M, Chauhan C, Abellera J (2020) Initial experience using autologous blood clot to promote closure in chronic pressure ulceration. Poster Presentation: Symposium on Advanced Wound Care, 2020. Available at: <https://bit.ly/3uF3RFY> (accessed 11.05.2021)
- Webster J, Scuffham P, Stankiewicz M, Chaboyer WP (2014) Negative pressure wound therapy for skin grafts and surgical wounds healing by primary intention. *Cochrane Database Syst Rev* (10): CD009261
- Woo K, de Gouveia Santos VLC, Alam T (2018) Optimising quality of life for people with non-healing wounds. *Wounds International* 9(3): 6–14
- Woo KY, Krasner DL, Kennedy B et al (2015) Palliative wound care management strategies for palliative patients and their circles of care. *Adv Skin Wound Care* 28(3): 130–40, quiz 140–2
- Wynn M, Freeman S (2019) The efficacy of negative pressure wound therapy for diabetic foot ulcers: A systematised review. *J Tissue Viability* 28(3): 152–60
- Young A, McNaught C-E (2011) The physiology of wound healing. *Surgery (Oxford)* 29(10): 475–79
- Zhao R, Liang H, Clarke E et al (2016) Inflammation in chronic wounds. *Int J Mol Sci* 17(12): 2085